


PATIENT

Lexi Smith

PRESENTING CLINICAL SIGNS

History: Initially presented for acting "off". Pacing and seems uncomfortable; cough/gag/
 -ECG report: Single and couplet VPCs. AIVR. Sotalol was recommended; however, was discontinued due to diarrhea.

SPECIES

Canine

-Current medications: Vetoryl 60 mg q24h; Sotalol 40 mg q12h.
 Pertinent echo findings (PAUS/MML 6/10/22): NSF with mild RH prominence

BREED

Boxer

SEX

FS

AGE

8 years

WEIGHT

77 lbs

HOLTER MONITOR FINDINGS AND RHYTHM ASSESSMENT

Time analyzed	23:53h
Mean heart rate	80bpm
Maximum heart rate	169bpm
Minimum heart rate	36bpm
VPCs	583 VPCs; primarily singles with 6 pairs, 15 bigeminy events
APCs	3 singles

Interpretation: Underlying normal sinus rhythm with apparently appropriate rate variation (diary not included). Isolated VPCs throughout with occasional couplets. VPCs are monomorphic. The couplets are not rapid; no R on T or obvious instability seen. Periods of bi, tri and quadrigeminy. Occasional sinus arrest during sleep.

Rhythm diagnosis: Sinus rhythm with isolated monomorphic VPCs and occasional couplets consistent with ARVC.

INTERPRETED BY

Maggie Machen Lamy,
 DVM, DACVIM
 (Cardiology)

RECOMMENDATIONS

The holter shows persistent ventricular premature contractions (VPCs) with low markers of malignancy. Compared to the prior recording (ie frequent couplets), this is considered reasonable control in an asymptomatic dog. Sotalol should be continued lifelong.

IMAGING PERFORMED BY

Wood River AH

Going forward, anesthetic risk remains mildly elevated. Avoid ketamine, telazol, dexdomitor (or other alpha-2 agonists) and acepromazine. Recommend having lidocaine CRI available for use in the event of worsening ventricular arrhythmias under anesthesia (CRI 50–75mcg/kg/min).

HOSPITAL NAME

Wood River AH

Fish oil supplementation is recommended for dogs with arrhythmias (1000mg of omega 3 and 6 once to twice daily as tolerated).

Monitor at home for collapse, exercise intolerance, and/or lethargy. Anesthesia is not recommended until good arrhythmic control is achieved. Lifelong mild to moderate activity restriction is advised.

REFERRING VET

Dr. Schuelke

Plan: Continue Sotalol as prescribed.

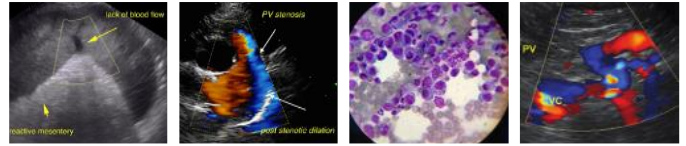
Recheck ECG (or ideally holter) and echocardiogram is recommended in 6 months to determine progression/control, sooner if any development of associated clinical signs such as syncope.

INVOICE

25319

DATE

7/14/22



PATIENT

Lexi Smith

SPECIES

Canine

BREED

Boxer

SEX

FS

AGE

8 years

WEIGHT

77 lbs

INTERPRETED BY

Maggie Machen Lamy,
DVM, DACVIM
(Cardiology)

IMAGING PERFORMED BY

Wood River AH

HOSPITAL NAME

Wood River AH

REFERRING VET

Dr. Schuelke

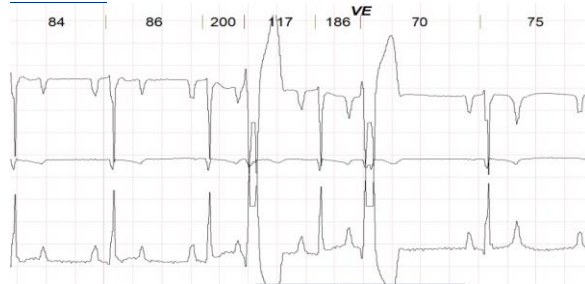INVOICE

25319

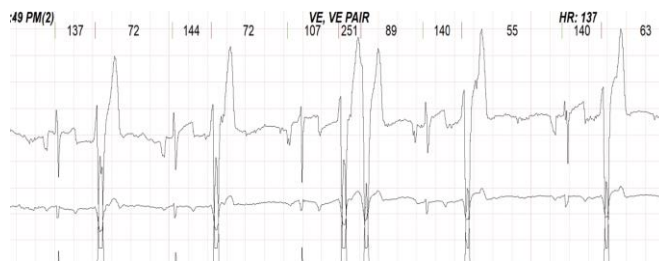DATE

7/14/22

IMAGES



Brief bigeminy



Couplet with bigeminy

The information and recommendations provided are based on the images presented by the referring veterinarian. No evaluation can be communicated regarding pathology that was not visible in the image/video clips provided.

Thank you for this referral. If the clinical or image interpretation does not parallel your findings or if I can be of any further assistance please contact me.

Maggie Machen Lamy, DVM
Diplomate of the American College of Veterinary Internal Medicine (Cardiology)
info@sonopath.com